



Restoration of vision after optic nerve lesions with noninvasive transorbital alternating current stimulation: a clinical observational study

A. Fedorov,^{a,c} S. Jobke,^c V. Bersnev,^a A. Chibisova,^a Y. Chibisova,^b C. Gall,^c
B. A. Sabel^c

^a*Polenov Russian Neurosurgical Institute, Saint-Petersburg, Russia*

^b*Mechnikov Medical Academy, Department of Neurology, Neurosurgery and Medical Genetics, Saint-Petersburg, Russia*

^c*Institute of Medical Psychology, Otto-von-Guericke University of Magdeburg, Magdeburg, Germany*

Background

Non-invasive current stimulation can induce neuroplastic changes in the normal brain, including visual system structures. Because it is not known if such plasticity is of clinical value, we wished to learn if vision restoration can be induced after optic nerve damage.

Methods

In an open-label, clinical observational study 446 patients with optic nerve lesions were treated with non-invasive repetitive transorbital alternating current stimulation (rtACS). Current bursts ($<1000 \mu\text{A}$, 5–20 Hz) were applied to induce phosphenes for one or two 10-day stimulation periods. Efficacy was assessed by monocular measurements of visual acuity and visual field (VF) size. EEG recordings at rest ($n = 68$) were made before and after treatment and global power spectra changes were analyzed.

Results

rtACS improved VF size in the right and left eye by 7.1% and 9.3% ($p < 0.001$), respectively. VF enlargements were present in 40.4% of right and 49.5% of left eyes. Visual acuity (VA) significantly increased in both eyes (right = 0.02, left = 0.015; $p < 0.001$). A second 10-day course was conducted 6 months in a subset of 62 patients and resulted in additional significant improvements of VA. Analysis of EEG power spectra revealed that VA and VF improvements were associated with increased alpha power. Increased theta power was observed in patients that had only VF enlargements but no VA change. In contrast, non-responders had increased delta power spectra in frontal and occipital areas.

Conclusions

rtACS leads to long-lasting improvements in VA and VF size and after-effects in EEG power spectra. Because physiological and clinical parameters are correlated we hypothesize that rtACS enhances

Correspondence: Anton Fedorov, Institute of Medical Psychology, Otto-von-Guericke University of Magdeburg, Leipziger Strasse 44, 39120 Magdeburg, Germany.

E-mail address: imp@med.ovgu.de

Submitted January 27, 2011; revised July 11, 2011. Accepted for publication July 12, 2011.

plasticity by inducing synchronization in different cortical regions, but the precise mechanisms needs further clarification. These encouraging results require confirmation by controlled clinical trials.

© 2011 Elsevier Inc. All rights reserved.

Keywords optic neuropathy; alternating current stimulation; vision recovery; restoration; neuroplasticity

Patients having impaired vision after brain damage can experience many limitations in everyday life activities such as deficits in visual orientation or detection of objects in visual space.^{1,2} Beyond a period of spontaneous recovery that typically lasts only for a few weeks or months^{3,4} in which the brain undergoes significant reorganization,⁵ the visual field defect (VFD) remains rather stable with no further improvement. However, when stimulating the visual field (VF) border by behavioral training, significant expansion of the VF can be achieved even many years after the damage.⁶⁻¹⁵ This argues for a well preserved neuroplasticity potential of the visual system in the adult and older age.

In Russia there has been a long-standing interest in improving VFs by electric stimulation methods that goes back to the pioneering studies by Bechtereva in the early 1970s.¹⁶ Together with Khilko and Shandurina,¹⁷ Bechtereva later developed an invasive electrical stimulation procedure to treat injured optic nerves during neurosurgical operations in partially or totally blind patients who had tumor, arachnoiditis, or traumatic brain injury (TBI). They observed significant recovery of vision 3-4 weeks after invasive stimulation which remained stable for over 2 years. This technique was replaced in 1990 by noninvasive stimulation approaches^{18,19} using alternating current stimulation protocols. Since then, a comprehensive analysis of physiologic data (EEG, VEP, PET) has revealed that repetitive transorbital alternating current stimulation (rtACS) not only results in functional improvements of the visual system, but that this protocol has a more widespread effect on cortical and subcortical systems.^{18,20,21} Because of the fundamental value of these observations, we have initiated a collaboration between our teams in St. Petersburg (Russia) and Magdeburg (Germany) to analyze and validate VF dynamics after rtACS. This study was also motivated by recent reports of cortical excitability changes after noninvasive transcranial magnetic or direct current stimulation in the motor,²²⁻²⁷ somatosensory,^{28,29} and visual system.³⁰⁻³⁴

By analyzing the original data collected in St. Petersburg (Russia), we carried out an independent assessment of the VF size changes in Germany. As we now demonstrate with the data obtained in a large sample, observational study, treatment of optic neuropathy patients with rtACS can improve visual acuity (VA) and VF size.

Methods

Subjects

Patients were treated during the period of 1993 to 2006 in Saint-Petersburg, Russia, at the Institute of the Human Brain and Neurosurgery Institute (by A.F.) and at the Mechnikov Medical Academy (by Y.C.). The patients were part of a clinical observational study, i.e., they did not participate in a formal clinical trial. In this study, data were collected during routine treatment before and after rtACS. The treatment protocol was approved by the local Ethical Committees in accordance with the Declaration of Helsinki with informed written consent from the patients. Available printed case histories of 446 patients were transferred to Germany for quantitative analysis. Our open-label, clinical observational study did not have a control group and both the patients and the attending physician were aware of the treatment modality. Therefore, experimenter bias cannot be excluded as a possible error source.

All patients had visual loss caused by damage of the optic nerve caused by either traumatic brain injury (TBI, $n = 209$), inflammation ($n = 134$), brain tumor ($n = 40$), or vascular lesions ($n = 63$) (Table 1).

The presence of optic neuropathy was documented by direct fundus ophthalmoscopy and the lesion ages were 6.8 ± 6.5 years (Table 1), i.e., well beyond the period of spontaneous recovery.

Exclusion criteria

Before treatment commenced, patients were screened to ascertain that there was neither clinical evidence of growing brain tumor anywhere in the body, nor confirmed autoimmune disease or chronic infections. Patients were also excluded if one of the following criteria applied: heart pacemakers, epileptic seizure within the last 3 years, photosensitive epilepsy as determined by EEG, mental diseases (schizophrenia), unstable diabetes, high blood pressure ($>160/100$ mm Hg), or instable or high level of intraocular pressure (i.e., >27 mm Hg). Considering that current is also going directly to the retina, patients were

Table 1 Patients demographic and initial vision deficit depends on optic neuropathy origin and performed course of noninvasive current stimulation

		Optic neuropathy origin			
All patients		Trauma	Inflammation	Tumor	Vascular
Patient group performing a first course of treatment (n = 446)	n = 446	n = 209	n = 134	n = 40	n = 63
Age (years)	37.9 ± 17.2	33.9 ± 14.0	32.0 ± 12.6	38.8 ± 16.7	62.8 ± 13.3
Sex (M/F)	316/130	173/36	103/31	11/29	29/34
Lesion age (years)	5.9 ± 8.0	6.8 ± 9.9	4.8 ± 5.6	6.6 ± 6.9	4.5 ± 5.1
Number of treated eyes	379 right eyes 363 left eyes	175 right eyes 151 left eyes	123 right eyes 126 left eyes	30 right eyes 30 left eyes	51 right eyes 56 left eyes
Pretreatment visual acuity decimal (M ± SD)					
Right eye	0.22 ± 0.31	0.25 ± 0.35	0.17 ± 0.26	0.24 ± 0.31	0.30 ± 0.29
Left eye	0.21 ± 0.31	0.28 ± 0.36	0.14 ± 0.24	0.21 ± 0.29	0.23 ± 0.27
Pretreatment visual field, cm² (M ± SD)					
Right eye	39.4 ± 28.2	36.4 ± 31.8	45.9 ± 23.6	35.7 ± 27.3	36.6 ± 24.1
Left eye	37.3 ± 28.3	36.7 ± 31.3	41.6 ± 24.9	26.5 ± 28.9	35.4 ± 26
Pretreatment visual field defect types, prevalence in %					
Contraction of the peripheral border	30	51.3	21.5	46.2	6.9
Central or paracentral scotoma	24.4	16.5	50.3	12.8	2.1
Scotoma and peripheral contraction	26.9	19.4	22.6	—	53.6
Residual islands	18.7	12.8	5.6	41	37.4
Patient group performing a second course of treatment (n = 62)	n = 62	n = 27	n = 15	n = 10	n = 10
Age at first stimulation (y)	36.8 ± 17.7	33.5 ± 14.2	27.7 ± 10.4	30.1 ± 11.0	63.7 ± 14.1
Sex (M/F)	40/22	22/5	11/4	4/6	3/7
Lesion age at first stimulation (y)	6.1 ± 6.4	5.8 ± 6.1	4.9 ± 5.2	6.2 ± 6.0	7.2 ± 8.0
Duration stimulation-free interval (mo)	8.9 ± 4.1	9.1 ± 4.4	7.9 ± 2.1	8.3 ± 3.3	9.3 ± 4.3

excluded if they had retinopathy, retinal detachment, or if there was a risk or recent history of hemorrhages.

Clinical evaluation

All patients (mean age 37.6 ± 17.8 years) underwent an ophthalmologic examination including VA, perimetry, and fundus examination. Two hundred ninety-eight patients had damage on both eyes and 148 only on one eye. VA was measured monocularly in refraction corrected patients using the Snellen test chart that was presented at a distance of 6 meters.

VFs of all patients were determined with a Russian perimeter (ShP-31) comparable to a Goldmann perimeter used in Western countries. During this kinetic perimetry, a (white) light stimulus was manually moved from the periphery toward the central VF until the patient pressed a button to indicate that the stimulus was seen. The stimulus size was 2 mm diameter and it was moved at a velocity of about 5 degrees per second. Meridians were tested in 15-degree steps. The patient's eye was positioned at a distance of 45 cm from the perimeter screen and the luminance of the stimulus and the background were set at 318 and 10.3 cd/m², respectively. Both eyes were tested in all patients but only data of impaired eyes were considered for statistical analysis. VFs were then quantified in

Germany by entering the VF plots into a planimetric computer image analysis system to determine VF size of the seeing visual field. Normal VF size is equal to 152 cm². VFDs were determined in 76.1% for right eye and 71.7% for left eyes and were classified to belong to the following types (1) contraction of the peripheral border with intact foveal region (30%), (2) central or paracentral absolute scotoma (24.4%), (3) combination of peripheral contraction with central scotoma (26.9%), and (4) complete VF loss with residual islands of vision (18.7%, Table 1).

Stimulation protocol

rtACS^{21,35} was applied with a multichannel device (Brainstim, Russia, a prototype of EBS Technologies GmbH, Kleinmachnow, Germany) generating weak currents of square or sinus wave pulses that were given in trains of stimulation. To perform the transorbital stimulation, four active multichannel stimulation electrodes were placed at the upper eyelids (two for each eye) with eyes closed. The reference electrode was positioned at the wrist on the right hand.

The specific stimulation protocol was individually adjusted based on prior clinical experience. The number of pulses per train was initially set at two and then was gradually increased up to nine pulses per train in the last of

the 10 daily sessions. The pulse trains were delivered consecutively to each of the four channels (without channel pooling) constituting one cycle. Each daily session consisted of 200 to 250 such cycles that were interrupted by five to seven 1 minute pauses during the daily session. For all patients each of the train pulse repetitions varied from 5 and 20 Hz randomly. Current intensity was individually adjusted according to how well patients perceived phosphenes during the diagnostic procedures when the current amplitude was gradually increased with 10 μ A step per second at pulse repetition of 5 Hz. The current level at which the patient started to perceive flickering light impressions (phosphenes) was defined as the “individual current threshold” that was then selected as the stimulation setting. Obtained current threshold intensities varied from 115 up to 756 μ A (mean value is $417 \pm 156 \mu$ A). During the period of the 10-day therapy (10 sessions), phosphene thresholds had a tendency to decrease.

About 10-15% of stimulated patients were unable to see phosphenes during the rtACS as the result of severe vision loss. In such cases the current adjustment was selected so that the skin perceptions under the electrodes (noticed as local tingling or vibration) were clear and well tolerated. rtACS was applied daily for 2 weeks (excluding weekend) with session length between 25-40 minutes.

Severe adverse effects after the therapy and during follow-up period were not observed. During the stimulation sessions about 10% of patients noticed minor pain or local warmth under the stimulation electrode or immediately after the session some vision blurring effects for 1-2 minutes. More rarely (<5%) patients complained about weak headache, drowsiness, or poor sleep. Also, blood pressure fluctuation and general fatigue were occasionally noticed.

A subset of patients (40 male and 22 female) received an additional 10-day treatment period within few months after the first course of stimulation. Typically, these patients had requested the additional treatment because they thought that the first session had helped them to see better so that this group was composed primarily of responders.

Neurophysiological evaluation

EEG recording

For further quantitative EEG analysis, 68 available pre- and posttherapy EEG records could be analyzed (from 34 responders and 34 nonresponders, respectively). The EEG records of most of the other patients (>75%) were documented only as inkjet writing EEG plots (Neurofax EEG-5532, Nihon Kohden, Japan) so that their digital data were not available for analysis. The 68 patient EEG subgroup can therefore be considered to be representative of the total patient sample. EEG was recorded using an Encephalan-131/3, (Medicom-Mtd, Russia) with 19 sintered Ag/AgCl-electrodes placed according to the 10-10 system, with both ear references and ground electrode positioned between Fz-F4. Electrode impedances were

always maintained below 10 k Ω . EEG was analogue filtered from 0.016 to 200 Hz, sampling range at 500 Hz. Resting EEG with eyes closed conditions was collected for a duration of 102 seconds for further analysis.

EEG data preparation and analysis

Data analysis was performed using Vision Analyzer (Brain Products, Munich, Germany). All records were visually inspected for artifacts, and epochs containing eye movements or electrode drifts were rejected. Preprocessing included the following parameters: low cutoff at 0.5 Hz and high cutoff at 50.0 Hz (24 db/oct), notch filter 50 Hz; data were also ocular corrected. EEG data were segmented into 1.024-second epochs. Results of FFT were averaged, exported to SPSS 15.0 in the following bands (delta 0.5-3.5 Hz, theta 4-7.5 Hz, alpha 8-12.5 Hz, and beta 13-25 Hz), and log10 normalized. To reduce 19 brain sites to the main seven brain areas of interest further averaging with neighboring electrodes was calculated as follows: frontal (F3, Fz, F4), central (C3, Cz, C4), parietal (P3, Pz, P4), left (F7, T3, T5), and right temporal (F8, T4, T6), and left (O1) and right occipital (O2). Finally, pre- and posttreatment values were summarized in 7×4 tables (seven brain regions; four frequency bands) for power spectra and frequency analysis. Two-sided *P* values were then calculated separately for all power spectra calculations for seven brain sites and alpha adjustments were made accordingly (*P* < 0.0071).

Statistical analysis

Summaries of patient records, VF charts and EEG results were transferred to Germany for data verification and statistical analysis. After the data were carefully screened with respect to data quality, particularly with regard to the VF border determinations, the pre-post differences of the seeing VF were quantified and analyzed with SPSS 15.0.

Results

First course of stimulation

Visual fields in total patient sample

The results of all 446 patients after the first stimulation course are summarized in Table 2.

The overall dimension of the VF after treatment was compared with baseline (i.e., baseline = 100% one-tailed t-test). The size of the VF relative to baseline of the right eye increased significantly from $39.4 \pm 28.2 \text{ cm}^2$ to $42.3 \pm 27.8 \text{ cm}^2$, i.e., a relative improvement of 7.1% (*P* < 0.0001). The VF in the left eye increased significantly by 9.3% (from $37.3 \pm 28.3 \text{ cm}^2$ to $40.8 \pm 28.5 \text{ cm}^2$, *P* < 0.001). These average changes were mainly caused by VF enlargements (>1% of VF size change) in 40.4% of the patients in the right eye and in 49.5% of the patients in the left eye as shown in Figure 1.

Table 2 Relative changes of visual acuity depends on optic neuropathy origin

Change pre versus post in percent	All patients	Trauma	Inflammation	Tumor	Vascular
Visual field OD in %	+7.1 ^a	+8.0 ^a	+3.9 ^a	+8.1 ^a	+13.2 ^a
Visual field OS in %	+9.3 ^a	+9.7 ^a	+6.5 ^a	+9.2 ^a	+15.3 ^a
Difference in VA OD	+0.02 ^a	+0.01 ^b	+0.02 ^a	+0.05 ^c	+0.04 ^b
Difference in VA OS	+0.015 ^b	+0.02 ^a	+0.01 (n.s.)	+0.02 (n.s.)	+0.01 ^b

VA = visual acuity.

^a $P < 0.001$.^b $P < 0.01$.^c $P < 0.05$; n.s. = not significant.

The VA of the right eye increased significantly from 0.23 ± 0.31 to 0.25 ± 0.33 ($P < 0.0001$) and in the left eye from 0.21 ± 0.31 to 0.23 ± 0.31 ($P < 0.0001$). Figure 2 shows typical VF dynamics in single cases including the subject with the largest extent of recovery.

VF increases were largest in patients with residual islands of vision inside an otherwise complete VF loss > contraction of the peripheral border with foveal region intact > central or paracentral absolute scotoma > combination of peripheral contraction with central scotoma.

TBI

Patients having TBI ($n = 209$) showed improvement of detection performance in kinetic perimetry from $36.4 \pm 31.8 \text{ cm}^2$ to $39.4 \pm 31.9 \text{ cm}^2$ (OD), i.e. a significant VF enlargement of 8% ($P < 0.0001$). In the left eye, the VF significantly increased by 9.7% ($36.7 \pm 31.3 \text{ cm}^2$ to $40.3 \pm 32.2 \text{ cm}^2$, $P < 0.0001$).

VA in both eyes slightly improved from 0.25 ± 0.35 to 0.26 ± 0.35 in the right eye ($P = 0.01$) and in the left eye from 0.28 ± 0.36 to 0.30 ± 0.37 ($P < 0.0001$).

Inflammation

In patients with VFDs caused by inflammation ($n = 134$), the VF in the right eye increased significantly by 3.9% (from

$45.9 \pm 23.6 \text{ cm}^2$ to $47.7 \pm 22.7 \text{ cm}^2$, $P < 0.0001$). Again, the left eye showed a greater improvement of 6.5% (from $41.6 \pm 24.9 \text{ cm}^2$ to $44.2 \pm 24.7 \text{ cm}^2$, $P < 0.0001$).

VA in these patients appeared to be inconsistent: although the VA in the right eye significantly increased from 0.17 ± 0.26 to 0.19 ± 0.27 ($P < 0.0001$), it remained unchanged in the left eye (0.14 ± 0.24 before rtACS versus 0.15 ± 0.24 after stimulation, $P = 0.361$).

Brain tumor

VF of the right eye in brain tumor patients ($n = 40$) increased significantly from $35.7 \pm 27.3 \text{ cm}^2$ to $38.7 \pm 26.8 \text{ cm}^2$, i.e., by 8.1% ($P < 0.001$). A 9.2% VF enlargement was also significant in the left eye ($26.5 \pm 28.9 \text{ cm}^2$ before rtACS versus $29.0 \pm 27.9 \text{ cm}^2$ after stimulation, $P < 0.0001$).

VA was similar to the results of the inflammation group. Although VA significantly increased from 0.24 ± 0.31 to 0.29 ± 0.35 in the right eye ($P = 0.04$), it remained statistically unchanged in the left eye (0.21 ± 0.29 to 0.23 ± 0.31 , $P = 0.076$).

Vascular disease

Patients with vascular lesions ($n = 63$) showed the greatest VF enlargements. VF of the right eye increased from $36.6 \pm 24.1 \text{ cm}^2$ to $41.5 \pm 22.9 \text{ cm}^2$, a significant improvement over baseline of 13.2% ($P < 0.0001$). The left eye showed a slightly greater improvement of 15.3% (from $35.4 \pm 26 \text{ cm}^2$ to $40.8 \pm 25.6 \text{ cm}^2$, $P < 0.0001$). VA of the right eye increased significantly from 0.30 ± 0.29 to 0.34 ± 0.32 ($P = 0.005$) and in the left eye from 0.23 ± 0.27 to 0.25 ± 0.28 ($P = 0.002$).

Stability of vision restoration and effects of a second treatment course

A subset of patients ($n = 62$, 40 male and 22 female) received an additional 10-day treatment period within few months after the first course of stimulation. Changes of clinical parameters were compared after the first stimulation course, at the beginning of the second course, and after the second course. Finally, we compared also results at baseline versus after the second treatment course. An overview of these results is shown in Table 3.

In general, VF of both eyes increased significantly after the first stimulation course (OD +9.0%, $P < 0.0001$, OS

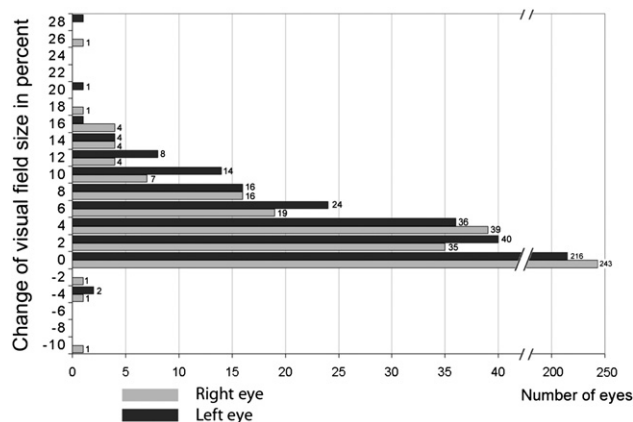


Figure 1 VF size enlargement (in % over baseline) (742 eyes), i.e., relative change, after first course of rtACS. Study results are displayed to show the response distribution for all patients.

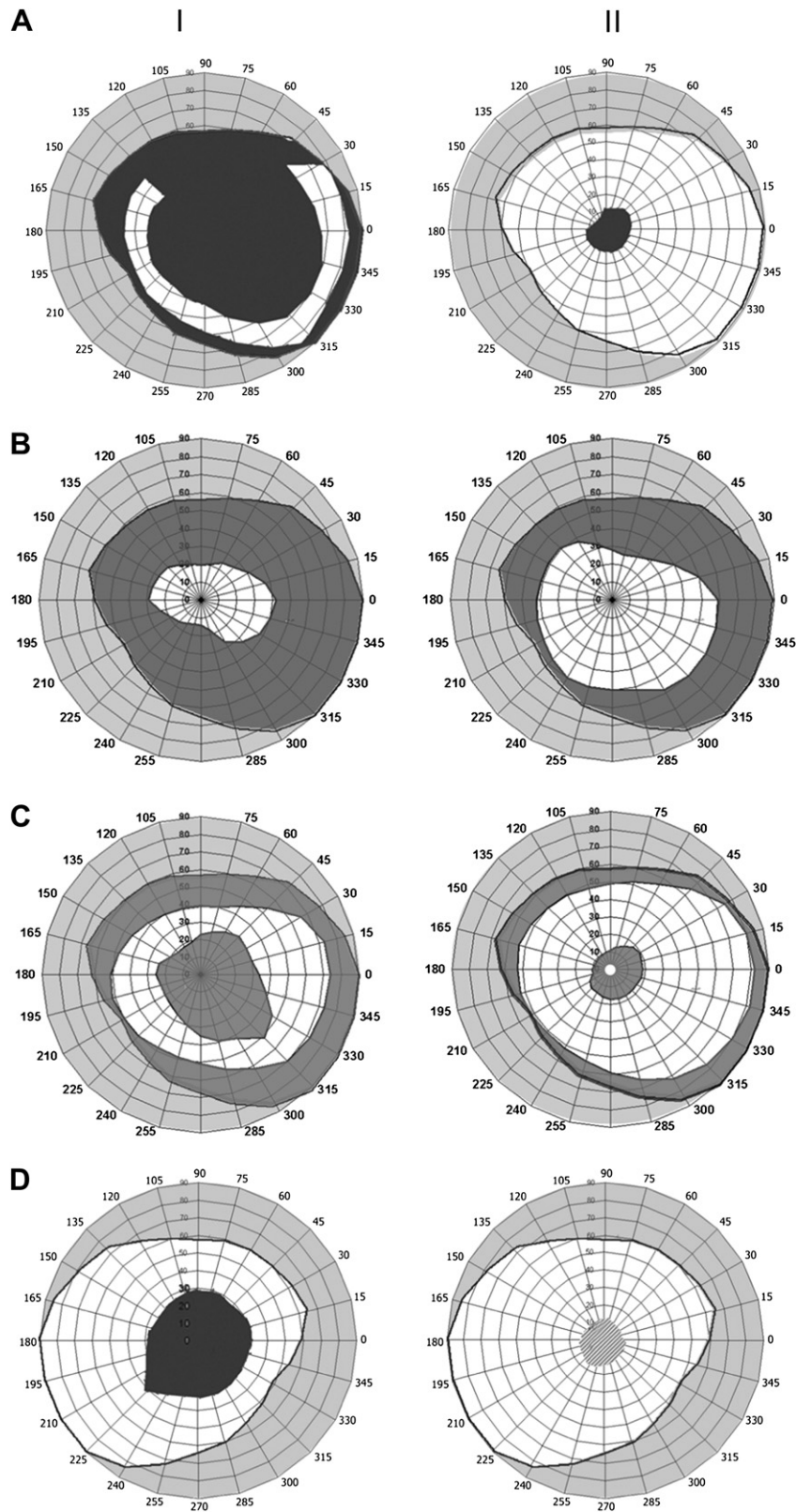


Figure 2 Full field perimetry before (I) and after (II) rtACS. Best recovered eye (A, post inflammation) and other typical cases (B, post tumor; C, TBI; D, vascular). Normal VF borders are shown by black contour lines. Intact areas are shown in white, dark grey = blind (absolute central scotoma in patients A, C, and D). The light grey area shows the position of the relative scotoma.

Table 3 Stability of vision restoration and effects of a second treatment course

Groups	Outcome measurement		Treatments effects			
			First course	Stability after 6 mon.	Second course	Total change
			Post I vs Pre I	Pre II vs Post I	Post II vs Pre II	Post II vs Pre I
All patients n = 62	Visual field in %	Right	+9.0 ^b	−4.6 ^c	+3.9 ^b	+8.0 ^a
		Left	+12.8 ^b	−5.6 (n.s.)	+4.9 (n.s.)	+11.8 ^b
	Difference in VA OD	Right	+0.02 (n.s.)	+0.03 (n.s.)	+0.01 (n.s.)	+0.07 ^a
		Left	+0.01 ^a	−0.01 (n.s.)	+0.02 ^a	+0.05 ^a
Trauma n = 27	Visual field in %	Right	+8.3 ^b	−8.5 ^c	+2.8 ^a	+1.9 (n.s.)
		Left	+13.9 ^b	−13.3 (n.s.)	+7.1 ^b	+6.3
	Difference in VA OD	Right	+0.00 (n.s.)	−0.04 (n.s.)	+0.01 (n.s.)	−0.02 (n.s.)
		Left	+0.00 (n.s.)	−0.01 (n.s.)	+0.00 (n.s.)	−0.03 (n.s.)
Inflammation n = 15	Visual field in %	Right	+4.8 ^c	−0.8 (n.s.)	+1.7 (n.s.)	+5.6 (n.s.)
		Left	+5.0 (n.s.)	−3.8 (n.s.)	+3.8 ^c	+4.8 ^c
	Difference in VA OD	Right	+0.02 (n.s.)	+0.17 (n.s.)	−0.01 (n.s.)	+0.18 ^c
		Left	+0.01 ^a	+0.02 (n.s.)	+0.01 (n.s.)	+0.13 ^c
Tumor n = 10	Visual field in %	Right	+6.6 ^c	+2.1 (n.s.)	+2.0 (n.s.)	+11.1 ^a
		Left	+9.1 ^a	+2.0 (n.s.)	+10.7 ^c	+23.2 ^a
	Difference in VA OD	Right	+0.05 (n.s.)	+0.01 (n.s.)	+0.01 (n.s.)	+0.07 (n.s.)
		Left	+0.06 (n.s.)	−0.02 (n.s.)	+0.03 (n.s.)	+0.04 (n.s.)
Vascular n = 10	Visual field in %	Right	+25.9 ^a	−7.4 (n.s.)	+11.1 ^c	+29.4 ^c
		Left	+26.5 ^a	−0.6 (n.s.)	+12.6 ^c	+41.5 ^b
	Difference in VA OD	Right	+0.06 (n.s.)	+0.03 (n.s.)	+0.05 (n.s.)	+0.14 ^a
		Left	+0.03 ^c	−0.04 (n.s.)	+0.03 ^c	+0.09 ^a

^a $P \leq 0.05$.^b $P \leq 0.01$.^c $P \leq 0.005$; n.s., not significant.

+12.8%, $P < 0.0001$). After a stimulation-free interval of nearly 9 months, the VF decreased by 4.6% in the right eye and by 5.6% in the left eye but this loss of restoration was not significant for OS ($P = 0.112$) and had a trend to be significant for OD ($P = 0.081$). After the second course of stimulation, the VF significantly increased again in the right (+3.9%, $P < 0.0001$) and left eye (+4.9%, $P < 0.0001$). Results of two courses revealed significant improvements of the VF areas (8%, $P = 0.012$ and 11.8%, $P = 0.005$). Before second stimulation period, VA for OD did not change significantly, but in OS it increased up to 0.02 ($P = 0.029$). Finally, the comparison with baseline has shown a trend for significant changes, OD (+0.07, relative change 28.7%, $P = 0.041$) and OS (+0.05, 23.8%, $P = 0.051$).

TBI

The subgroup of patients having TBI ($n = 27$) showed a significant VF enlargement in both eyes after the first treatment period (OD +8.3%, $P = 0.003$, OS +13.9%, $P = 0.002$). After a stimulation-free interval of 9.1 months, the VF size decreased nonsignificantly in the right (−8.5%, $P = 0.075$) and the left eye (−13.3%, $P = 0.099$). After a second course of stimulation, the VF enlargements were again significant in both eyes (OD +2.8%, $P = 0.031$, OS +7.1%, $P = 0.002$). Final changes were positive but nonsignificant. VA remained statistically unchanged after the first stimulation course, after the stimulation-free interval, and after the second course of treatment.

Inflammation

The subgroup of patients having VFDs caused by inflammation processes ($n = 15$) did not show any significant changes in their VF, neither after the first nor after the second course of treatment. Regarding the VA, the only significant change occurred in the left eye after the first course of treatment (+0.01, $P = 0.017$).

Brain tumor

VFs of this subgroup of patients with VFDs caused by a brain tumor ($n = 10$) increased significantly by 9.1% in the left eye after the first course of stimulation ($P = 0.034$). The VF of the right eye remained statistically unchanged (+6.6%, $P = 0.065$). During the stimulation-free interval, the VF slightly enlarged about 2.0% in both eyes, but this was not significant on either eye. The second course of treatment did not result in any significant changes although there was a descriptive enlargement of 2.0% in the right ($P = 0.351$) and 10.7% in the left eye ($P = 0.095$). The right eye showed 11.1% VF increases over baseline ($P = 0.043$) and the left eye 23.2% ($P = 0.026$). VA did not increase significantly at the final diagnostics after the second rtACS course (OD = +0.07 and OS = +0.04).

Vascular disease

In the subgroup of patients with vascular diseases ($n = 10$), the VF increased after the first course of treatment by +25.9% in the right ($P = 0.033$) and +26.5% in the left

Table 4 EEG power spectra changes (A) and analysis of frequency domains (B) pre vs. post rtACS

Areas of interest	Delta			Theta			Alpha			Beta		
	Pre	Post	Diff	P	Pre	Post	Diff	P	Pre	Post	Diff	P
Power spectra (A). Log normalized power spectra, μV^2												
Forward	1.53	2.08	0.54	0.000	1.48	1.76	0.28	n.s.	1.46	1.77	0.31	n.s.
Middle	1.60	2.13	0.53	0.001	1.45	1.74	0.30	n.s.	1.28	1.65	0.37	n.s.
Back	1.39	1.98	0.60	0.001	1.28	1.61	0.34	n.s.	1.12	1.48	0.37	0.003
Left hemisphere	1.48	2.02	0.54	0.001	1.40	1.69	0.29	n.s.	1.25	1.58	0.33	n.s.
Right hemisphere	1.56	2.08	0.52	0.001	1.48	1.75	0.26	n.s.	1.45	1.78	0.34	n.s.
Occipital left	1.54	2.36	0.83	0.005	1.52	2.07	0.55	n.s.	1.68	2.31	0.63	n.s.
Occipital right	1.57	2.35	0.78	0.006	1.53	2.04	0.51	n.s.	1.66	2.33	0.68	n.s.
Frequency(B) Log normalized value of frequency, Hz												
Forward	0.39	0.24	-0.15	0.001	0.71	0.72	0.02	n.s.	0.95	0.97	0.02	n.s.
Middle	0.39	0.26	-0.14	0.002	0.71	0.73	0.02	n.s.	0.95	0.97	0.02	n.s.
Back	0.39	0.26	-0.13	0.002	0.72	0.74	0.02	n.s.	0.96	0.98	0.02	n.s.
Left hemisphere	0.39	0.25	-0.14	0.002	0.70	0.73	0.02	n.s.	0.96	0.98	0.02	n.s.
Right hemisphere	0.39	0.26	-0.13	0.002	0.70	0.73	0.03	n.s.	0.96	0.98	0.02	n.s.
Occipital left	0.39	0.26	-0.13	0.001	0.72	0.74	0.02	n.s.	0.96	0.97	0.02	n.s.
Occipital right	0.39	0.27	-0.13	0.002	0.72	0.73	0.01	n.s.	0.97	0.98	0.01	n.s.

eye (trend at $P < 0.01$). During the stimulation-free interval, the VF slightly decreased but this was not significant. The second course of treatment did not result in significant VF enlargements (OD +11.1%, $P = 0.086$, OS +12.1%, $P = 0.076$). When the baseline before the 1st course is compared to the follow-up of the 2nd course the VF increase is significant for the left eye and a trend of improvement was seen for the right eye (OD +29.4%, $P = 0.078$, OS +41.5%, $P = 0.005$).

Electrophysiologic results

EEG power spectra

Results of the power spectra and frequency analyses are presented in Table 4. rtACS led to marked changes in the absolute power spectra in all brain bands, except theta. Taken together reliable power spectra increases were seen for delta rhythms in all seven brain areas, for alpha only for the occipital areas in both hemispheres and for beta in frontal, middle, and occipital sites, also in both hemispheres.

Analysis of frequency domains

This analysis revealed significant and reliable decreases only for delta EEG bands. When considering the group average, theta, alpha, and beta rhythms showed no reliable frequency changes, but intraindividually significant changes of alpha-rhythm power spectra were seen in 33% of the cases.

Analysis of EEG data for responders and nonresponders

An additional analysis was carried out to evaluate possible EEG pattern differences in patient with good vision recovery (responders) compared with those that did not recover much or not at all (nonresponders). For this analysis we considered the data of 34 patients for whom EEG records were available both before and after therapy. Ten patients with severe vision loss were excluded from further calculation because they had no measurable VF charts or their VA could not be quantified. After this exclusion, 24 complete cases were available for analysis. The criteria to be assigned to responders were VA increase of at least 20% change over baseline or at least a 5% VF enlargement over baseline. This criterion led to the following sample size: nonresponders ($n = 4$; group I), improved both VA and VF ($n = 5$; group IIa), only VA improved ($n = 3$; group IIb) or only VF improved ($n = 12$; group IIc). The difference of power spectra pre- and poststimulation (log10 normalized power spectra) was calculated. The comparison between each of four groups was made for each EEG band. Channels were pooled for the areas of interest (AOI) as forehead (Fp1, Fp2, F7, F3, Fz, F4, F8), middle part (T3, C3, Cz, C4, T4), and back of the head (T5, P3, Pz, P4, T6, O1, O2). One-way ANOVA analysis with the factor group was used to calculate significant differences.

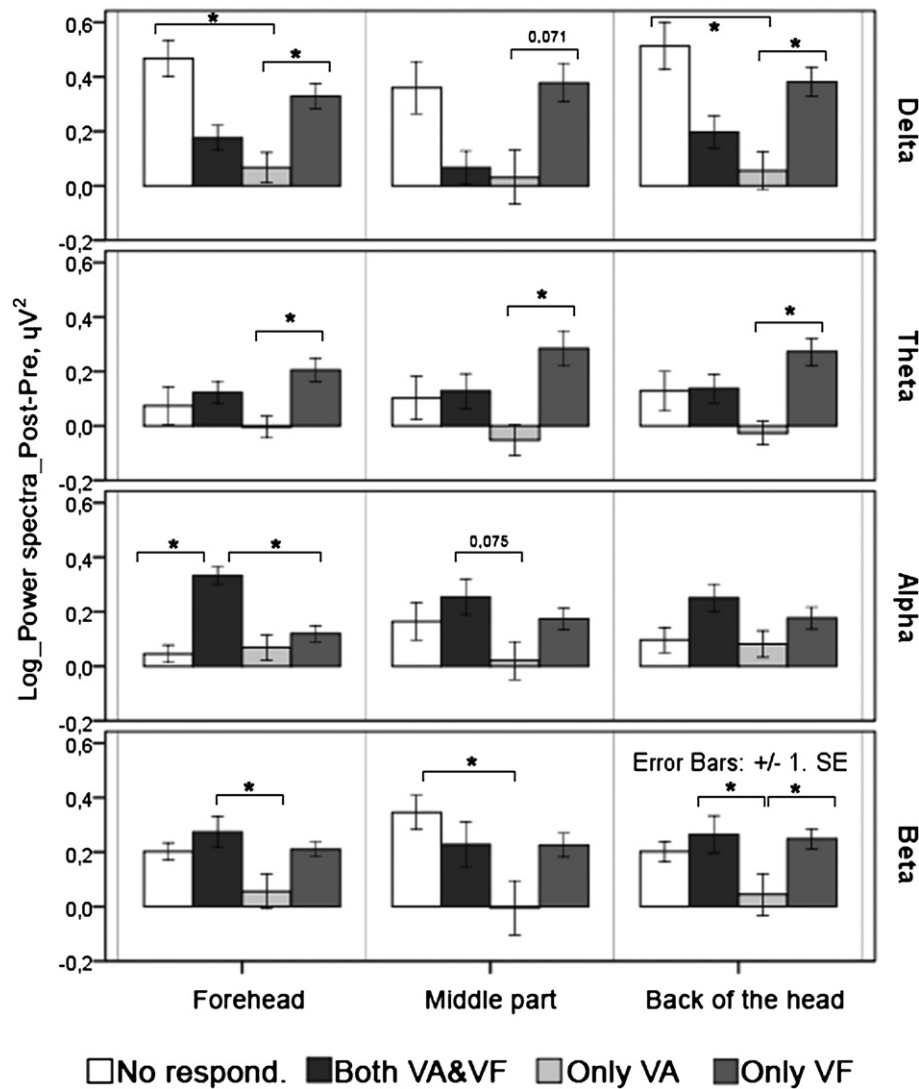


Figure 3 Difference of power spectra changes after rtACS for responders (group IIa: both VA and VF improved, group IIb: only VA improved, group IIc: only VF improved) and nonresponders. Analysis of EEG power spectra revealed that improvements of both VA and VF were associated with increased alpha power ($P < 0.05$ in forehead between responders and nonresponders). Theta power increase was found in patients that had only VF enlargements ($P < 0.05$ for all regions). In contrast, nonresponders showed an increase of delta power spectra in forehead and parieto-occipital areas ($P < 0.05$ between responders and none).

As Figure 3 shows, responders had certain EEG patterns that were associated with vision recovery. Nonresponders showed profoundly larger delta power in forehead and back of the head areas in groups IIa and IIb. In contrast, there were no differences in theta waves between responders and nonresponders, but they were associated with isolated VF enlargements (patients in group IIc showed significantly more theta power versus group IIb, who improved only in VA).

Our results demonstrate that there is a special role for alpha rhythms as a possible marker of visual recovery. We found that patients from group IIa (improved both VA and VF) showed markedly increased alpha power in forehead regions when compared with nonresponders. Patients with improved VF (IIc) also had a tendency of greater alpha

power. On the other hand, the isolated increase of VA improvements required less alpha power. Changes in the beta band were less specific markers of AC stimulation-induced recovery in all groups. However, group IIb showed increased beta waves. In the EEG study, significant differences were found between responders and nonresponders in the midsection of the brain.

Factors associated with clinical outcome

A nonparametric correlation analysis was calculated to assess possible factors that might predict outcome. VF improvements and VA change correlated positively with patient age (VF: correlation coefficient $r = 0.126$, $P = 0.014$; VA: $r = 0.103$, $P = 0.047$) and with the origin of

optic nerve lesion, more profound VF enlargement were associated with posttumor and vascular neuropathy ($r = 0.118$, $P = 0.024$). There was also an impact of the lesion age on outcome: we found a weak negative correlation with VA changes ($r = -0.105$, $P = 0.046$), i.e., higher age was associated with less marked VA improvements. Unilateral or bilateral lesions did not influence outcomes.

Discussion

A 10-day course of noninvasive rtACS in patients with optic neuropathy led to significant improvements over baseline of VA and VF enlargements. We found average VF size improvements of 7.1% and 9.3% for right and left eye, respectively. Best results were seen in patients with optic nerve damage of vascular origin as they improved their VFs by 13.5% (OD) and 15.3% (OS), respectively. This average change was due to VF enlargements in 40.4% of the patients in the right and 49.5% in the left eye when 1% was used as a change criterion. VA significantly increased in both eyes (right = 0.02, left = 0.02; $P < 0.001$). Although the size of the VF slightly decreased again after a stimulation-free interval of nearly 9 months, these declines were minor and nonsignificant. When a second treatment course was subsequently applied in a subset of patients, significant additional VF enlargements occurred in TBI patients and there was a positive trend for patients with vascular disease. Calculating the differences of clinical outcomes after two courses showed that total changes of VF areas and VA difference was significant. After the second course of treatment VA showed additional improvement of 28.7% for right and 23.8% for left eye (first course effect was lower: 10.8% and 6.6%, respectively). Thus, rtACS application produced stable improvements of visual functions and a second course led to further improvements.

Although the results of our clinical observational study with a large patient sample are very encouraging, the study design has a number of limitations that need to be addressed in future experiments. First, a placebo-controlled, randomized, and double blind clinical trial is required because we cannot be certain if or to what extent in the current study experimenter or subject bias contributed to the results. However, all patients undergoing therapy were hoping to achieve improvements but not all patients did. About 45-50% of the patients improved while the other half of the sample did not. This is similar to results of a placebo-controlled, randomized study in patients where vision restoration was induced by vision training (Kasten et al., 1998a).⁷ Based on this similarity, we assume that our data were not subject to any major experimenter bias beyond expected variability.

Another limitation of the study is that we did not quantify eye movements during perimetry. Though the patients were asked to keep their visual attention at the

fixation point during perimetry, we cannot determine whether and to what extent eye movement contributed to the VF border shifts. Similar concerns were raised when visual field enlargements were observed after a vision restoration training method. However, the experimental evidence shows that vision restoration is not typically associated with eye movement changes and that eye movements do not increase after training but actually slightly decrease while fixation ability increases.¹³ There is also no rational why current stimulation would affect eye movements during the diagnostic sessions. Furthermore, VA and EEG results are independent measures and cannot be explained by eye movements in any way.

Yet another limitation of the current clinical observations study was that the Goldman-like kinetic perimetry did not allow us to determine areas of residual vision ("ARV" or "relative defects"), which play an important role in the process of recovery; these areas are the most likely places where restoration takes place^{7,8,14,36,38} and measuring ARVs would have provided a more sensitive measure of change.

Despite these methodologic limitations, the study is a first indication of a possible therapeutic effect of rtACS in the field of visual impairment because we observed parallel changes in VF size, VA, and EEG power spectra changes. Interestingly, the similarity of restoration extent and variability among patients in our study are strikingly similar to those observed after training,³⁶ suggesting that both might rely on similar mechanisms.

Our study is in agreement with the hypothesis that activating residual vision can improve function, possibly through the capacities of the adult visual system for plasticity after visual system damage.³⁷ "Neuroplasticity" is a well-established concept in other functional systems of the brain such as the motor system, somatosensory system, and others.³⁸ There is also no apparent reason why the visual system should have less plasticity potential.³⁹ In fact, in adult animals receptive fields can spontaneously change their size and position after deafferentation in the lateral geniculus⁴⁰ or visual cortex.⁴¹⁻⁴³ Evidence of lateral interactions in vision restoration is compatible with this view.

The question arises as to possible mechanisms that mediate restoration by noninvasive alternating current stimulation. In contrast to invasive approaches (such as retina implants or deep brain stimulation), noninvasive stimulation is not aimed at "replacing" the lost retinal cells, neuronal circuitry or stimulating brain nuclei locally. Rather, rtACS is provided to stimulate the retina trans-orbitally to induce retinal ganglion cells to fire action potentials and subsequent activation of the striate cortex with possible influences on the level of brain physiologic networks, potentially affecting the synchronization state of these neuronal networks. In this context a study by Francis et al.⁴⁴ is of interest who stimulated hippocampal slices and

found that even weak electric fields (approximately 180 $\mu\text{V}/\text{mm}$) led to synchronization of the stimulated neurons. Also, electrical brain stimulation is known to produce EEG synchronization in epilepsy patients⁴⁵ and leads to after effects in healthy subjects.⁴⁶

We also made additional (non-EEG) observations suggesting that the clinical changes are mediated by “central” mechanism. Specifically, we noted VF improvements to be homolateral in both eyes, i.e., they occurred mostly on the right side of the VF (i.e., in the left hemisphere). This corresponds nicely with the greater alpha-power increase in the left occipital region. Thus, the change likely involves postchiasmatic levels of the visual system and is probably not related to repair at the site of the pathology, i.e., the optic nerve injury.

Averaged EEG data obtained at least 24 hours after rtACS revealed long-lasting after effects as profound power spectra changes across different brain regions at EEG bands. Taken together, our findings in responders versus nonresponders revealed a somewhat ambiguous result. Alpha- and beta-power spectra improvements is the expected band, surprisingly, the delta band also increased its power, which is not what was stimulated. This is not only opposite to our prediction but also opposite to our most recent findings in a prospective study (unpublished). And more consistent data were obtained after analysis of EEG changes was performed separately from patients who responded to the therapy versus those that did not. We found that improvements of both VA and VF were strongly associated with increased alpha power. Our data are compatible with observations by Zaehle et al.⁴⁷ who stimulated normal subjects with ACS in the alpha-band and found power spectra changes in this band that outlasted the stimulation period. Theta waves were found in patients who had only VF enlargements. We presume that the activation of the theta-rhythm in the posterior associative areas may reflect a new interaction between the specific and nonspecific systems in the regulation of sensory functions.

In contrast, nonresponders showed increased delta power in forehead and back of the head areas. It was found that delta-waves in the projection of the frontal lobe reflect the readiness of different brain cortices for visual perception.⁴⁸ The presence of the delta-activity in parietooccipital parts of the brain could relate to an existing functional disconnection of high-ordered visual cortices to perform visual processing of an increasing sensory flow.

In summary, the EEG “after-effect” of rtACS lead to correlated electrophysiologic and clinical measures. However, the precise relationship of physiologic and behavioral sign of plasticity seem to be rather complex and more detailed analysis have to be carried out in future studies.

In view of these findings we now propose the hypothesis that noninvasive, pulsed alternating current stimulation increases neuronal network synchronization in a lasting

fashion. Our EEG results are compatible with this “synchronization hypothesis” and suggest lasting bilateral synchronous waves in the alpha- and theta-ranges in central and occipital brain areas.

Brain areas were found to be changed simultaneously; EEG power spectra changes were seen not only in occipital regions (alpha-power band) but also in other brain areas (different bands). This is in line with observations that spontaneous recovery from optic neuritis mostly involves activation of extrastriate cortical and subcortical structures,⁴⁹ indicating a more widespread network change in the damage brain.

In patients with optic nerve damage activation of V1 and V2 cortices is significantly reduced.⁵⁰ Yet, the primary, deafferented cortex can still respond to visual stimulation. In a study using transcranial magnetic stimulation in patients with pregenicular blindness, visual percepts (phosphenes) could still be elicited in retinotopic positions of the “blind” cortex even many years after blindness.⁵¹ The deafferented visual cortex is apparently still capable of visual information processing, despite the many years of missing neuronal input. In fact, Poggel et al.¹⁴ found spontaneous phosphenes during natural recovery and after training-induced improvements of the VF in the blind regions and this was interpreted as a sign of “denervation supersensitivity.” In our current study, we induced such phosphenes artificially by rtACS and this improved visual functions. Thus, it is reasonable to argue that rtACS might increase sensitivity of visual structures and other secondary areas throughout the brain, perhaps as the result of increased synchronization. According to the “residual vision activation theory,” there is considerable potential for vision recovery after damage and different brain mechanisms and regions are involved.³⁸ However, the precise mechanisms of action of rtACS needs more detailed scientific exploration.

In summary, our observational study, together with a previous single case report² is the first quantitative evidence that rtACS may improve VFs, VA, and alter EEG activity in patients with optic neuropathy. It is now necessary to obtain more insight into the mechanisms of action and to confirm these clinical findings in a well-controlled randomized, placebo-controlled clinical trial which is now described in the accompanying paper.⁵²

References

1. Gall C, Lucklum J, Sabel BA, Franke G. Vision- and health-related quality of life in patients with visual field loss after postchiasmatic lesions. *Invest Ophthalmol Vis Sci* 2009;50(6):2765-2776.
2. Gall C, Fedorov AB, Ernst L, Borrmann A, Sabel BA. Repetitive transorbital alternating current stimulation (rtACS) in optic neuropathy—single case study. *Neurorehab* 2010;27(4):335-341.
3. Kerrison J, Lynn M, Baer C, et al. Stages of improvement in visual fields after pituitary tumor resection. *Am J Ophthalmol* 2000;130: 813-820.
4. Zhang X, Kedar S, Lynn M, Newman N, Bioussé V. Natural history of homonymous hemianopia. *Neurology* 2006;66(6):901-905.

5. Plant G, Kermode A, Turano G, et al. Symptomatic retrochiasmal lesions in multiple sclerosis: clinical features, visual evoked potentials, and magnetic resonance imaging. *Neurology* 1992;42(1):68-76.
6. Kasten E, Sabel BA. Visual field enlargement after computer training in brain-damaged patients with homonymous deficits: an open pilot trial. *Restor Neurol Neurosci* 1995;8:113-127.
7. Kasten E, Wüst S, Sabel BA, Behrens-Baumann W, Sabel BA. Computer-based training for the treatment of partial blindness. *Nat Med* 1998;4(9):1083-1087.
8. Kasten E, Poggel DA, Muller-Oehring E, et al. Restoration of vision II: residual functions and training-induced visual field enlargement in brain-damaged patients. *Restor Neurol Neurosci* 1999;15(2-3):273-287.
9. Kasten E, Poggel D, Sabel BA. Computer-based training of stimulus detection improves color and simple pattern recognition in the detective field of hemianopic subjects. *J Cogn Neurosci* 2000;12(6):1001-1012.
10. Kasten E, Mueller-Oehring E, Sabel BA. Stability of visual field enlargements following computer-based restitution training—results of a follow-up. *J Clin Exp Neuropsych* 2001;23(3):297-305.
11. Wüst S, Kasten E, Sabel BA. Blindsight after optic nerve injury indicates functionality of spared fibers. *J Cogn Neurosci* 2002;14(2):243-253.
12. Sabel BA, Kenkel S, Kasten E. Vision restoration therapy (VRT) efficacy as assessed by comparative perimetric analysis and subjective questionnaires. *Restor Neurol Neurosci* 2004;22(6):399-420.
13. Kasten E, Bunzenthall U, Sabel BA. Visual field recovery after vision restoration therapy (VRT) is independent of eye movements: an eye tracker study. *Behav Brain Res* 2006;175(1):18-26.
14. Poggel DA, Kasten E, Muller-Oehring EM, Bunzenthall U, Sabel BA. Improving residual vision by attentional cueing in patients with brain lesions. *Brain Res* 2006;1097(1):142-148.
15. Jobke S, Kasten E, Sabel BA. Vision restoration through extrastriate stimulation in patients with visual field defects: a double-blind and randomized experimental study. *Neurorehabil Neural Repair* 2009;23(3):246-255.
16. Bechtereva NP, Bondartchuk AN, Gretchin VB, et al. Structural-functional organization of the human brain and the pathophysiology of the parkinsonian type hyperkineses. *Confin Neurol* 1972;34:14-17.
17. Bechtereva NP, Shandurina AN, Khilko VA, et al. Clinical and physiological basis for a new method underlying rehabilitation of the damaged visual nerve function by direct electric stimulation. *Int J Psychophysiol* 1985;2(4):257-272.
18. Shandurina AN, Panin AV. Clinical and physiological analysis of periorbital transcutaneous electrical stimulation method for damaged optic nerve and retina. *Fiziol Cheloveka* 1990;16(1):53-59.
19. Chibisova AN, Fedorov AB. Method for restoring vision function in case of optic nerves atrophy, diseases of retina, and amblyopia. RU2102046, Patent Bull of Rus Fed 1998; N 2.
20. Chibisova AN, Fedorov AB, Fedorov NA. Neurophysiological characteristics of compensation-recovery processes in the brain during rehabilitation of the neurosensory impairment of the visual and acoustic systems. *Fiziol Cheloveka* 2001;27(3):14-21.
21. Fedorov AB, Chibisova AM, Tchibisova JM. Impulse modulating therapeutic electrical stimulation (IMTES) increases visual field size in patients with optic nerve lesions. *Int Congr Series* 2005;1282:525-529.
22. Hallett M. Transcranial magnetic stimulation: a primer. *Neuron* 2007;55(2):187-199.
23. Siebner HR, Lang N, Rizzo V, et al. Preconditioning of low-frequency repetitive transcranial magnetic stimulation with transcranial direct current stimulation: evidence for homeostatic plasticity in the human motor cortex. *J Neurosci* 2004;24(13):3379-3385.
24. Boggio PS, Castro LO, Savagim EA, et al. Enhancement of non-dominant hand motor function by anodal transcranial direct current stimulation. *Neurosci Lett* 2006;404:232-236.
25. Hesse S, Werner C, Schonhardt EM, Bardeleben A, Jenrich W, Kirker SGB. Combined transcranial direct current stimulation and robot-assisted arm training in subacute stroke patients: a pilot study. *Restor Neurol Neurosci* 2007;25:9-15.
26. Boros K, Poreisz C, Münchau A, Paulus W, Nitsche MA. Premotor transcranial direct current stimulation (tDCS) affects primary motor excitability in humans. *Eur J Neurosci* 2008;27:1292-1300.
27. Carson RG, Kennedy NC, Linden MA, Britton L. Muscle-specific variations in use-dependent crossed-facilitation of corticospinal pathways mediated by transcranial direct current (DC) stimulation. *Neurosci Lett* 2008;441:153-157.
28. Dieckhofer A, Waberski TD, Nitsche M, Paulus W, Buchner H, Gobbele R. Transcranial direct current stimulation applied over the somatosensory cortex—differential effect on low and high frequency SEPs. *Clin Neurophysiol* 2006;117:2221-2227.
29. Antal A, Brepohl N, Poreisz C, Boros K, Csicsak G, Paulus W. Transcranial direct current stimulation over somatosensory cortex decreases experimentally induced acute pain perception. *Clin J Pain* 2008;24:56-63.
30. Antal A, Kincses TZ, Nitsche MA, Bartfai O, Paulus W. Excitability changes induced in the human primary visual cortex by transcranial direct current stimulation: direct electrophysiological evidence. *Invest Ophthalmol Vis Sci* 2004;45:702-707.
31. Antal A, Nitsche MA, Kincses TZ, Kruse W, Hoffmann K-P, Paulus W. Facilitation of visuo-motor learning by transcranial direct current stimulation of the motor and extrastriate visual areas in humans. *Eur J Neurosci* 2004;10:2888-2892.
32. Antal A, Nitsche MA, Paulus W. Transcranial direct current stimulation and the visual cortex. *Brain Res Bull* 2006;68:459-463.
33. Chaieb L, Antal A, Paulus W. Gender-specific modulation of short-term neuroplasticity in the visual cortex induced by transcranial direct current stimulation. *Vis Neurosci* 2008;25:77-81.
34. Antal A, Paulus W. Transcranial direct current stimulation and visual perception. *Perception* 2008;37:367-374.
35. Fedorov A, Chibisova Y, Szymaszek A, Alexandrov M, Gall C, Sabel BA. Non-invasive alternating current stimulation induces recovery from stroke. *Restor Neurol Neurosci* 2010;28(6):825-833.
36. Guenther T, Mueller I, Preuss M, Kruse R, Sabel BA. Treatment outcome prediction model of visual field recovery using self-organizing-maps. *IEEE Trans Biomed Eng* 2009;56(3):572-581.
37. Kasten E, Wuest S, Sabel BA. Residual vision in transition zones in patients with cerebral blindness. *J Clin Exp Neuropsychol* 1998;20(5):581-598.
38. Sabel BA, Henrich-Noack P, Fedorov A, Gall C. Vision restoration after brain and retina damage: "The residual vision activation theory". *Prog Brain Res* 2011;192:199-262.
39. Weiller C, Ramsay SC, Wise RJ, Friston KJ, Frackowiak RS. Individual patterns of functional reorganization in the human cerebral cortex after capsular infarction. *Ann Neurol* 1993;33(2):181-189.
40. Fregni F, Pascual-Leone A. Technology insight: noninvasive brain stimulation in neurology—perspectives on the therapeutic potential of rTMS and tDCS. *Nat Clin Pract Neurol* 2007;3(7):383-393.
41. Eysel UT, Gonzalez-Aguilar F, Mayer U. A functional sign of reorganization in the visual system of adult cats: lateral geniculate neurons with displaced receptive fields after lesions of the nasal retina. *Brain Res* 1980;181(2):285-300.
42. Gilbert CD, Wiesel TN. Receptive field dynamics in adult primary visual cortex. *Nature* 1992;356(6365):150-152.
43. Chino YM, Smith EL 3rd, Kaas JH, Sasaki Y, Cheng H. Receptive-field properties of deafferented visual cortical neurons after topographic map reorganization in adult cats. *J Neurosci* 1995;15(3):2417-2433.
44. Eysel UT, Schweigart G, Mittmann T, et al. Reorganization in the visual cortex after retinal and cortical damage. *Restor Neurol Neurosci* 1999;15(2-3):153-164.
45. Francis JT, Gluckman BJ, Schiff SJ. Sensitivity of neurons to weak electric fields. *J Neurosci* 2003;23(19):7255-7261.
46. Schindler K, Elger CE, Lehnertz K. Changes of EEG synchronization during low-frequency electric stimulation of the seizure onset zone. *Epilepsy Res* 2007;77(2-3):108-119.

47. Zaehle T, Rach S, Herrmann CS. Transcranial alternating current stimulation enhances individual alpha activity in human EEG. *PLoS One* 2010;5:e13766.
48. Kostandov EA. The formation of a set based on illusory representations and during the perception of concrete visual stimuli. *Fiziol Cheloveka* 1999;25(1):5-14.
49. Werring DJ, Bullmore ET, Toosy AT, et al. Recovery from optic neuritis is associated with a change in the distribution of cerebral response to visual stimulation: a functional magnetic resonance imaging study. *J Neurol Neurosurg Psychiatry* 2000;68:441-449.
50. Duncan RO, Sample PA, Weinreb RN, Bowd C, Zangwill LM. Retinotopic organization of primary visual cortex in glaucoma: a method for comparing cortical function with damage to the optic disk. *Invest Ophthalmol Vis Sci* 2007;48(2):733-744.
51. Gothe J, Brandt SA, Irlbacher K, et al. Changes in visual cortex excitability in blind subjects as demonstrated by transcranial magnetic stimulation. *Brain* 2002;125(Pt 3):479-490.
52. Gall, Sgorzaly S, Schmidt S, Brandt S, Fedorov AB, Sabel BA. Improved subjective visual functioning and vision-related quality of life in optic neuropathy by non-invasive alternating current stimulation. *Brain Stim* 2011. In press